

# Surgical Management of an Epidemic of Penile Amputations In Siam

**Kasian Bhanganada, MD, FACS, Bangkok, Thailand**

**Tu Chayavatana, MD, Bangkok, Thailand**

**Chumporn Pongnumkul, MD, Bangkok, Thailand**

**Anunt Tonmukayakul, MD, Bangkok, Thailand**

**Piyasakol Sakolsatayadorn, MD, Bangkok, Thailand**

**Krit Komaratai, MD, Bangkok, Thailand**

**Henry Wilde, MD, FACP, Bangkok, Thailand**

*Chai Yen* can be translated from Thai as keeping a cool heart. It is said to describe a valued Siamese behavioral trait, namely of suppressing anger and avoiding confrontation. Reports of violent attacks by wives against philandering husbands in Thailand's press demonstrate that *Chai Yen* has its limits. It became fashionable in the decade after 1970 for the humiliated Thai wife to wait until her husband fell asleep so that she could quickly sever his penis with a kitchen knife. A traditional Thai home is elevated on pilings and the windows are open to allow for ventilation. The area under the house is the home of the family pigs, chickens, and ducks. Thus, it is quite usual that an amputated penis is tossed out of an open window, where it may be captured by a duck. The Thai saying, "I better get home or the ducks will have something to eat," is therefore a common joke and immediately understood at all levels of society.

The Thai epidemic of penile amputations started around 1973 and peaked in 1977. It was fueled by graphic press reports including at least one series of interviews with prominent Thai women who, almost unanimously, stated that they endorsed this method of retribution. A survey of surgeons at major Bangkok, Khon Koen, and Chiang Mai hospitals resulted in an estimate of 100 such incidents between 1973 and 1980. A considerable amount of expertise in managing penile amputations has therefore evolved throughout the kingdom's medical centers. Siriraj Hospital is a 2,000 bed teaching institution which

From the Department of Surgery, Siriraj Hospital, Mahidol University, Bangkok, Thailand.

Requests for reprints should be addressed to Henry Wilde, MD, Regional Medical Center, American Embassy Bangkok, APO San Francisco, California 96346.

acts as a receiving medical center for much of metropolitan Bangkok. This is a report of the Siriraj Hospital Trauma Division's experience with 18 attempted reanastomoses of amputated penises.

There were eighteen amputations and reimplantations. Eight of the patients came directly to the Trauma Division of Siriraj Hospital; the others were managed by Siriraj surgeons at private hospitals. Management was not uniform in the first 14 cases. The clinical course was stormy, complicated by skin and partial glans necrosis, urethral fistula, diminution of the size of the organ, and unproved ability or inability to achieve an erection. It was soon recognized that the ideal way to handle these patients would be by microsurgical techniques. However, such techniques require special equipment, instruments, and training which are not readily available. Efforts were therefore made to develop a simple and standard technique of management that could be performed by any general surgeon. It was applied in the last four cases treated at Siriraj Hospital and produced acceptable results.

## Technique

**Preparation of the amputated specimen:** The time elapsed between amputation and arrival at the emergency room was usually between 30 minutes and 2 hours. The specimen was presented in various forms: wrapped in a handkerchief, in pieces of newspaper, in a banana leaf, or in a plastic bag full of ice. All specimens were grossly contaminated. The following procedures were carried out: (1) The specimen was unwrapped and placed in a large basin containing saline or Ringer's solution. It was carefully cleaned until all visible contaminants and coagulated blood had been removed. (2) The specimen was then transferred to a smaller basin containing ice cold (about 4° C) saline

or Ringer's solution. One ml of 2 percent lidocaine, 5,000 units of heparin, and 500,000 units of penicillin were added to every 500 ml of this solution. All blood was then squeezed out of the specimen, and gentle squeezing was continued until the exuding solution was clear and free of blood. (3) The specimen was then transferred into a new sterile basin filled with the same ice cold solution. It was now ready for reimplantation.

**Preparation of the stump:** Patients presented using various means of hemostasis. Local self-applied pressure with a towel or pressure on the stump by hand were the most usual. Bleeding was still significant in all instances. For preparation, the stump was exposed and a rubber band was placed tightly around the base to prevent further bleeding. If no stump was present, mosquito forceps were used to clamp bleeders. The entire perineum was then shaved and cleaned with either sterile water or saline solution.

**Preparation of the patient:** An effort was made to reassure the patient and to explain to him that he could anticipate prolonged hospitalization but that a reasonably successful outcome could be expected. Blood was drawn for typing and crossmatching. About 1,000 ml of blood was usually required. Ringer's lactate solution was started as an intravenous infusion. Preanesthetic medications were administered as indicated, and general or spinal-epidural anesthesia was performed.

**Surgical procedure (Figure 1):** All remaining skin was carefully removed from the amputated penis starting from the prepuce. The rubber band, if applied, was removed from the stump and all bleeding points were carefully tied using 4-0 silk. The dorsal vein of the penile stump was, however, not ligated. The amputated part was then aligned with the stump in as natural a position as possible. The septum that separates the two corpora cavernosa was sutured using 3-0 chromic catgut. Three to four interrupted sutures were adequate. Each corpus cavernosus was anastomosed using interrupted 3-0 plain catgut sutures. The tunica albuginea was brought together using interrupted stitches of 3-0 chromic catgut. The deep dorsal vein of the penis was anastomosed using 6-0 or 8-0 atraumatic vascular suture material. Anastomosis of the severed urethra together with the corpus spongiosum was then performed using four to six interrupted sutures of 4-0 chromic catgut. A urethral catheter was used as a splint. The catheter was, however, removed after surgery to reduce the risk of infection. A subcutaneous tunnel was prepared in the scrotum where the denuded penis was buried, leaving the glans exposed. Next, a suprapubic cystostomy was prepared to divert urine flow temporarily. The average time needed to perform this procedure was less than 2 hours.

**Postoperative care and secondary surgery:** Routine postoperative procedures included administration of analgesics, immobilization, and administration of antibiotics (usually kanamycin and ampicillin). If there was evidence of skin necrosis of the exposed glans penis, necrotic tissue was removed and the entire glans was also buried in the scrotum. The patient was discharged after 10 days if there were no complications. He was encouraged to urinate naturally by clamping the cystostomy tube. Urethral dilatation was performed after 2 weeks if necessary. Separation of the penis from the scrotum could usually be performed 2 months postoperatively. Scrotal skin was used to cover the denuded, previously buried penis. The cystostomy tube was removed at the same time.

**Follow-up care:** Urethral dilatations were only performed if strictures became a problem. Sexual activity was encouraged after the second operation as soon as the skin graft had fully healed.

## Case Reports

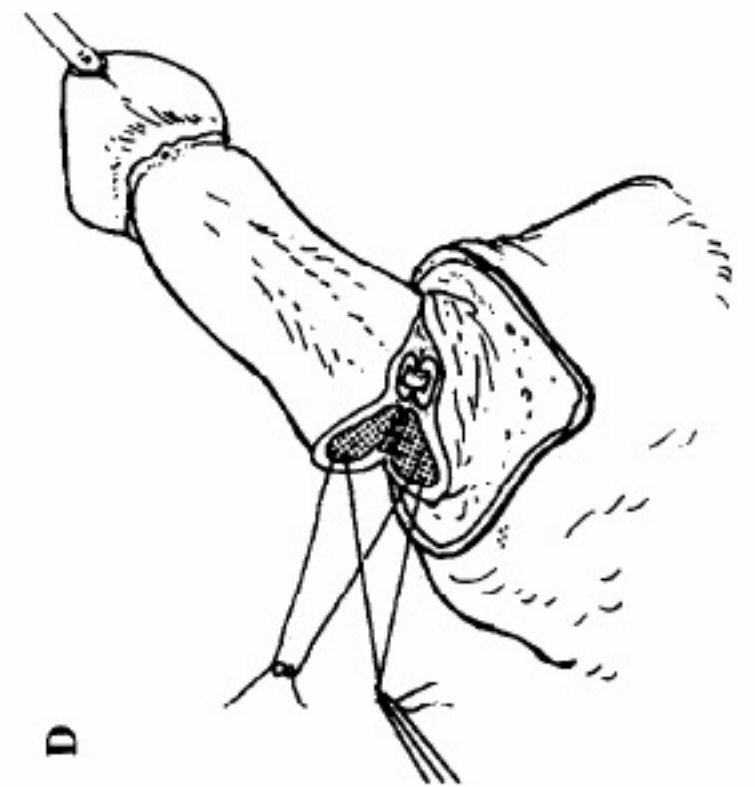
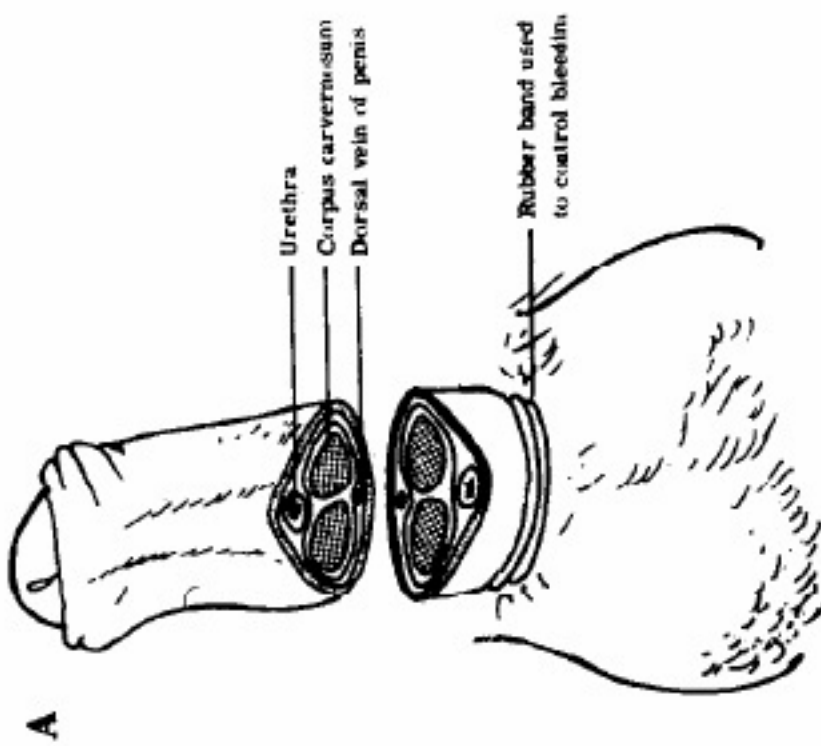
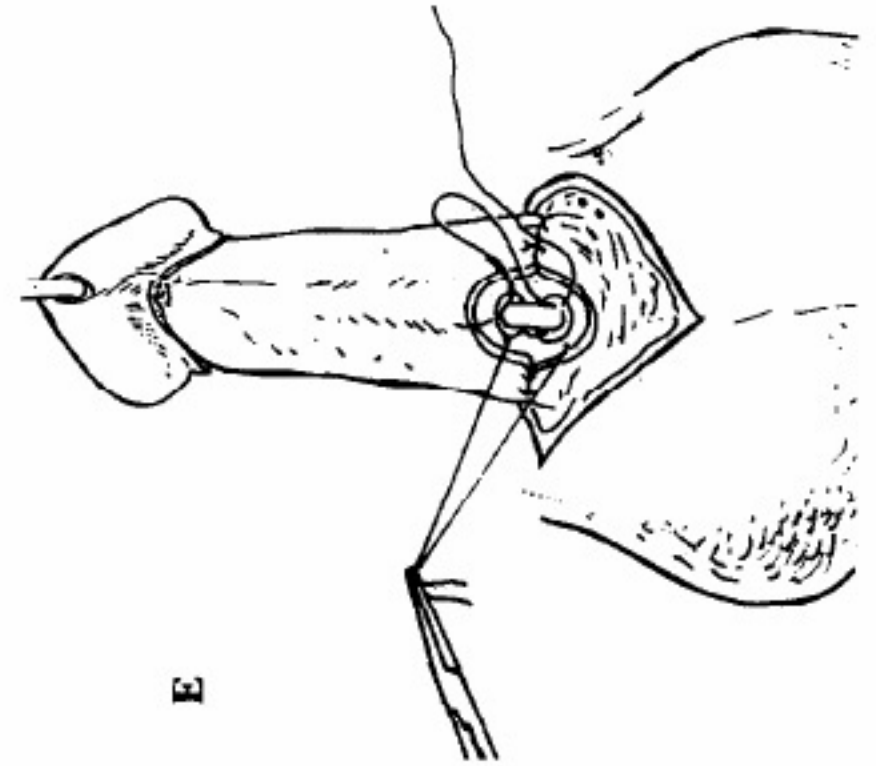
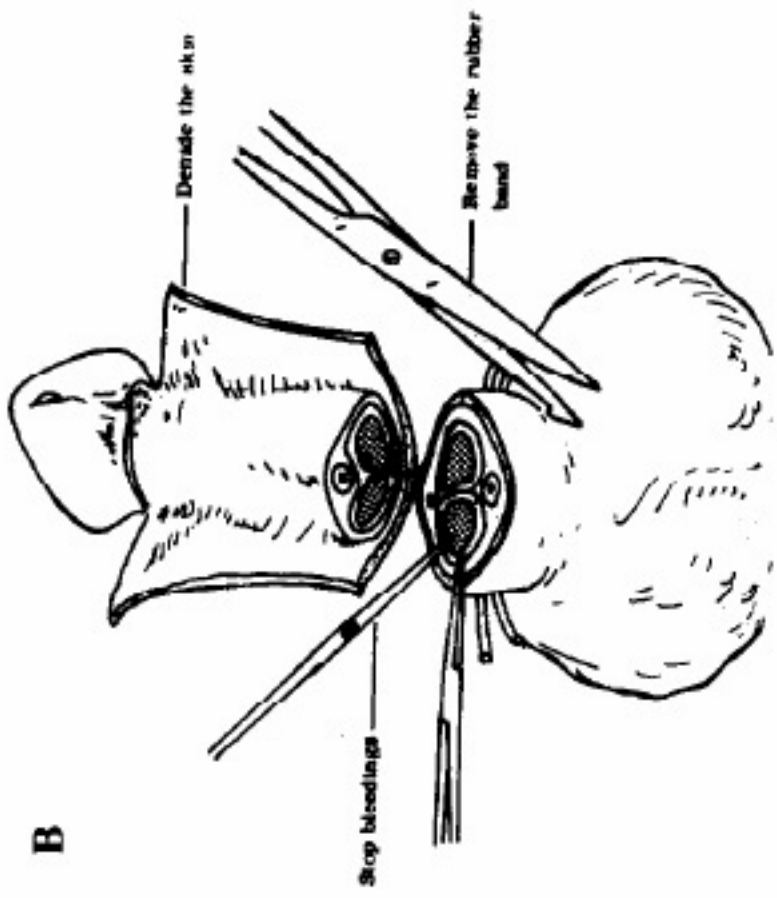
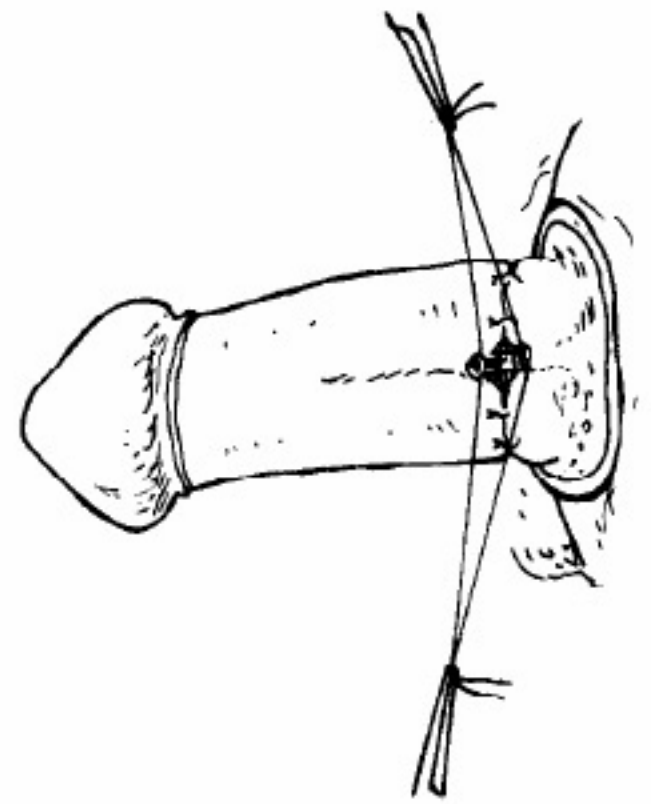
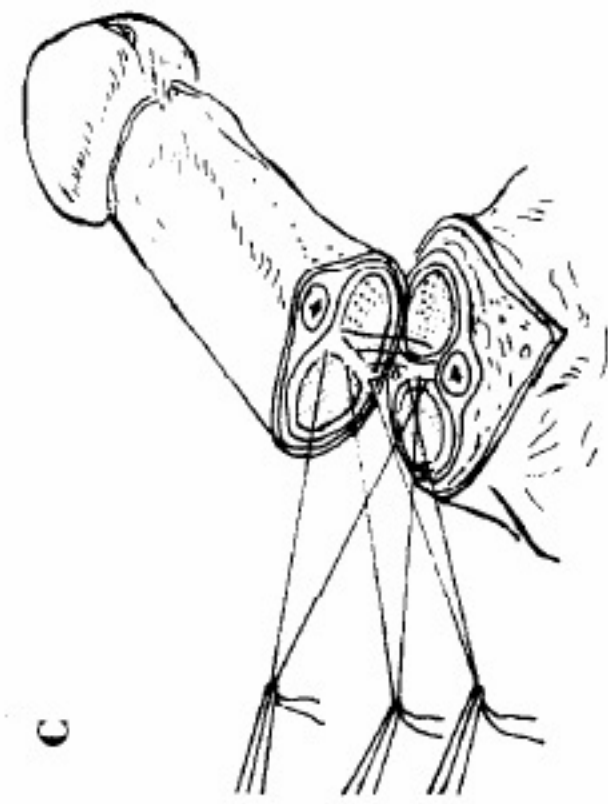
**Case 1. Patient 3:** A 35 year old man was brought to Siriraj Hospital with his amputated penis in a plastic bag. His wife had cut it off while he was sleeping. This was the first case we encountered. It took the patient about 1 hour to reach the hospital. Examination revealed a pale and anxious patient who was not in shock. There was profuse bleeding from the large wound which left no stump and included a small part of scrotum. Anastomosis of the corpus cavernosum, tunica albuginea, and deep dorsal vein was performed. The reimplanted penis looked well-vascularized immediately after operation and remained so until the third postoperative day when the skin became dusky. The necrotic dermis was removed on the eight postoperative day, and healthy subcutaneous tissue was evident. Split-thickness skin grafting was performed on the 19th day, and the patient remained hospitalized for a total of 45 days. He was seen 1 month after discharge. Examination revealed no urethral stricture and normal urination. The patient stated that he was able to achieve erection and ejaculation, neither of which was, however, confirmed.

**Case 2. Patient 11:** A 33 year old man was brought to the hospital 30 minutes after his penis was cut off with a straight razor by his wife. The reimplantation was done much in the same fashion as in Patient 3. This time we were better prepared, and the superficial dorsal vein of the penis was also reanastomosed in the hope that this might help prevent skin necrosis. On the following day, the color of the skin nevertheless changed, and necrosis ensued. The necrotic skin was removed on the third postoperative day. Split-thickness skin grafting was performed on the 10th postoperative day. This patient, unfortunately, was lost to follow-up.

**Case 3. Patient 12:** A 32 year old man had verbal altercations with his wife concerning his sexual inadequacy, after which he used a razor blade to amputate his penis. He was brought to the hospital by his wife who had wrapped the amputated penis in a piece of banana leaf. It took 8 hours before the reimplantation was performed. The anastomosis was acceptable but skin necrosis appeared as expected. Dermal excision and skin grafting were performed with good result. The patient was, however, lost to follow-up.

**Case 4. Patient 13:** This 36 year old man was brought to the hospital by his wife. She had just amputated her husband's penis with a kitchen knife. There was no stump left in this case and bleeding was profuse. Part of the scrotum was also severed. The reimplantation took place 2 hours after admission. Skin necrosis was again evident on the third postoperative day. Removal of the skin and split-thickness grafting were accomplished with good results. There was a urethral stricture that required occasional dilatation. He reported normal sexual intercourse 1 month after the last operation and a modest erection was observed (Figure 2).

**Case 5. Patient 15:** A 34 year old man was brought to the hospital after his girlfriend removed his penis using a



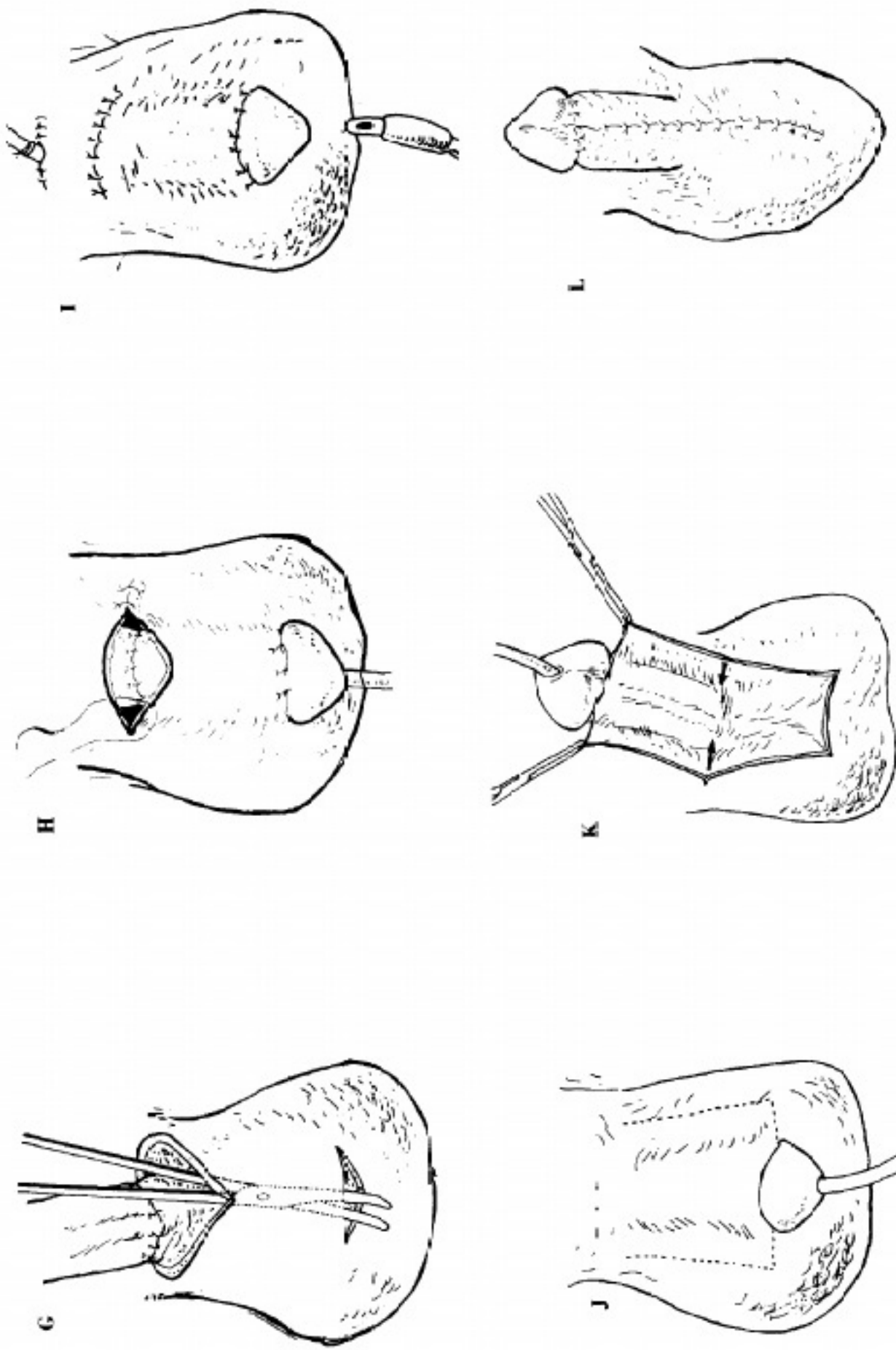
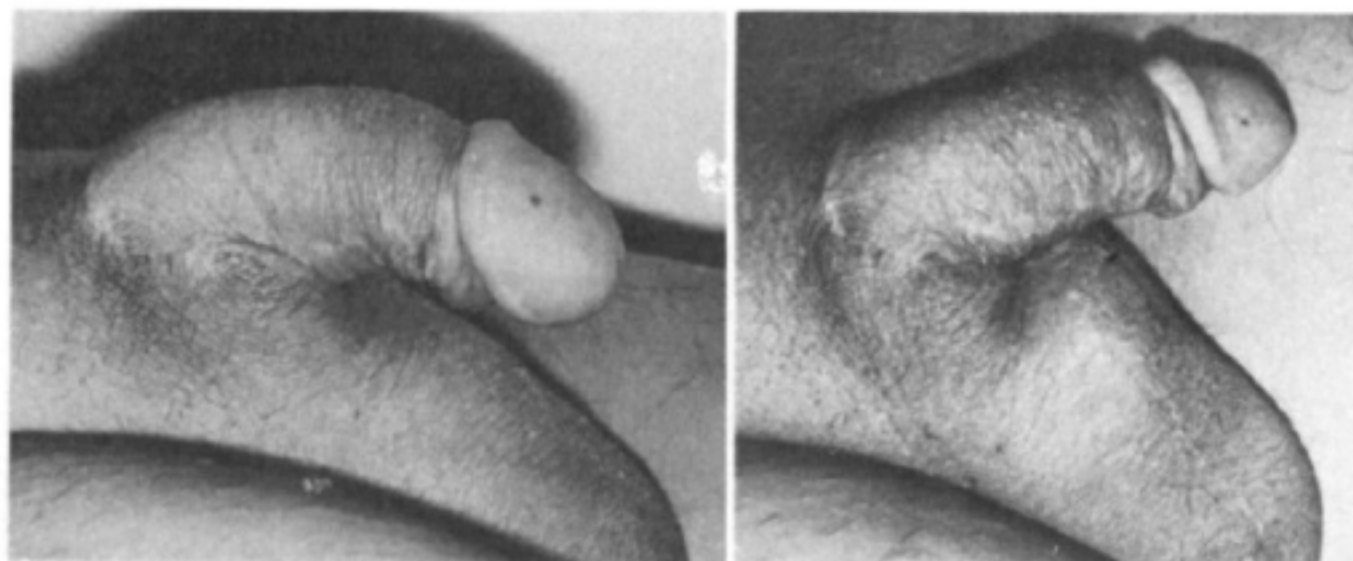


Figure 1 Reimplantation using the burrowing method. A, anatomic relations; B, hemostatic; C, suture the median septum; D, the corpus cavernosum; E, anastomosis of the urethra; F, anastomosis of the dorsal vein of the penis; G, make a tunnel underneath the skin of the scrotum; H, the denuded, anastomosed penis in the tunnel, leaving the glans; I, close the wound; J, after 6 to 8 weeks, make incisions over the scrotal skin along the penile shaft. A catheter is reintroduced to facilitate manipulation of the penis; K, raise the penis shaft from the scrotal sac along with the skin covering it; L, suture the skin edge together to separate the penis from the scrotal sac.



**Figure 2.** Photograph of the flaccid (left) and semi-erect (right) penis in Patient 13.

kitchen knife. The amputated part was brought by a friend wrapped in a handkerchief. Reimplantation of the penis was started about 2 hours after the incident, using the burrowing technique (Figure 1). Seven days postoperatively, the skin covering the glans penis showed signs of ischemic necrosis. It was debrided and the glans was buried into the scrotal sac along with the shaft. Two months later, the entire penis was separated from the scrotal sac. The patient was able to urinate through his urethra, and the suprapubic cystostomy tube was removed. When seen 1 month later, the patient claimed that he could achieve erection and ejaculation.

**Case 6. Patient 16:** A 34 year old man was brought to the hospital having had his penis amputated by his wife using a knife. The cut was close to the pubis and part of the scrotum was missing. Bleeding was profuse. Reimplantation was performed 4 hours after injury using the same burrowing technique as in Patient 15 (Figure 3). Recovery was uneventful. Separation of the penis from the scrotum was performed 3 months after the initial operation. This patient was lost to follow-up for 1 year but then came back, having remarried, and stating that he was able to have normal intercourse with his new wife.

### Comments

Reimplantation of the amputated penis has been discussed in the medical literature as far back as 1929 [1]. Reports of such procedures, however, have appeared only sporadically since 1961 [2-9]. The most common complications reported have been necrosis of the skin covering the amputated penis or of the glans, infection, fistulas, and strictures of the urethra. McRoberts et al [5] of Seattle first described in 1968 a new technique that produced fewer complications and better results. It was an improvisation of the urethroplasty for hypospadias developed by Cecil [10]. The penile skin of their patient was avulsed from the shaft, and the only salvation for the denuded penis appeared to be burial in a scrotal tunnel. The procedure proved to be successful and led us to modify it for our series. Since the skin in our early patients almost always necrosed, we decided that it

might be better to remove it before the anastomosis was performed. We thus hoped to avoid having to remove devitalized skin after performing the anastomosis and also believed that the shaft might obtain additional blood supply from within the scrotum and reduce the risk of partial necrosis of the glans. We adopted this technique for our last four patients, and the results were satisfactory. The time lapse between burying the anastomosis and lifting it out varied from 6 to 12 weeks. Although microvascular anastomosis should give the best results, such a procedure can only be performed by a specially trained surgeon who needs expensive equipment, and the procedure is time consuming. An average of 8 hours operating time was required in our later, as yet unpublicized, cases in which microsurgical techniques were used.

The method described herein is simple and can be performed in almost any hospital equipped with basic surgical tools. We believe that penile reimplantation should be successful regardless of the method of anastomosis, provided that the amputated part is not mutilated, decomposed, or partially eaten by a duck. Skin and glans necroses are, however, very common. The technique presented here has proved to be valuable for preserving sexual and urinary function with minimal complications or changes in appearance.

Viability of the amputated part proved to be surprising. Eight hours was the longest period of time between the incident and successful surgical repair. In two more recent cases, the amputated parts had to be fished out of septic tanks. They had been flushed down the toilet bowl by the angry wives. Microvascular anastomosis nevertheless resulted in functioning organs.

The age range of our patients was from 20 to 44 years (Table I). One amputation may have been an accident. Of four patients who had self-inflicted injuries, at least one (the American student) was clearly psychotic. Angry wives seemed to favor the kitchen knife as an instrument for amputation. Amputation

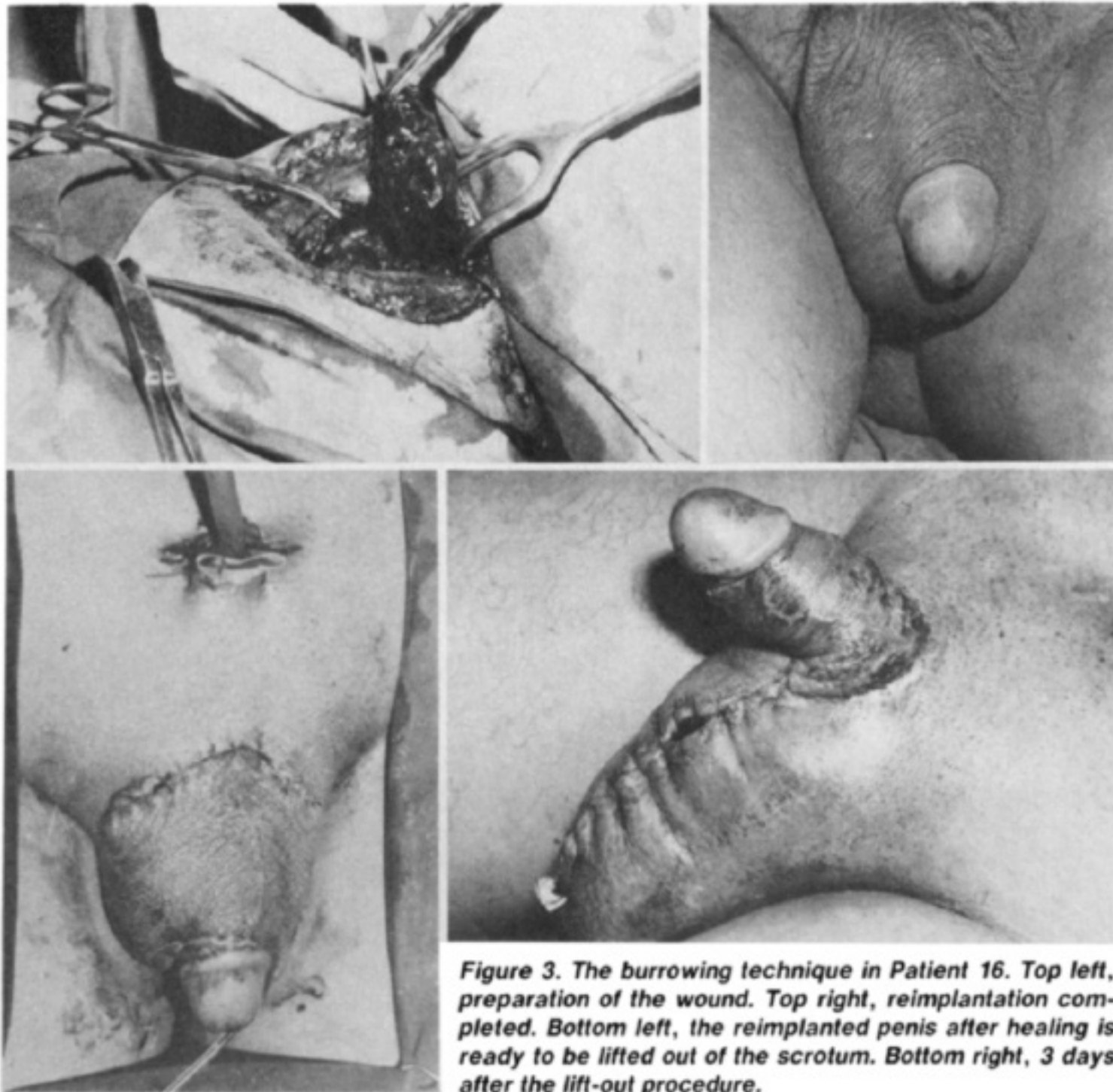


Figure 3. The burrowing technique in Patient 16. Top left, preparation of the wound. Top right, reimplantation completed. Bottom left, the reimplanted penis after healing is ready to be lifted out of the scrotum. Bottom right, 3 days after the lift-out procedure.

was total in nine of the wife-inflicted cases and often included parts of the scrotum—testimony to the fact that the attacking wives had *lued yen* (cold blood) when they decided to act. Only four attacks left a short penile stump. There was, however, no apparent difference in the surgical and functional results between patients who had total amputations and those who had partial amputations. There was a significantly shorter and less stormy hospital course in the last four patients described when ample experience had developed in management, and the scrotal burrowing technique of McRoberts et al [5] was used. No patients in whom we used a microsurgical technique were included in this series. We now have a small collection of men who had penile reimplantation using microsurgical techniques. They have done extremely well and will be described at a future time.

Tactile and pain sensation of the reimplanted organ was lost in all cases when tested by the pinprick method. Sensation did not return, even after 2 years of follow-up (when this was possible). This was also true in later cases where microvascular techniques were used. All patients who returned for follow-up examination could feel pressure when the penis was squeezed by the examiner. Most described their

organ as numb but expressed little concern about this defect. Some volunteered that this actually was an advantage since it allowed them to delay ejaculation and have prolonged coitus.

We have had only limited experience with patients who had incomplete amputations in which the cut did not transect the entire penis and where a small skin strip was left as a connecting bridge. Several such patients have, however, been managed at other Thai medical centers. Anecdotal reports have indicated that survival rates of the distal penile skin are much better in such cases. Direct anastomosis without burying and skinning of the amputated segment may well suffice in such patients.

The inadequate follow-up record in our series is, unfortunately, rather typical of the patient population and the practices at Siriraj Hospital. The poor people of metropolitan Bangkok often do not have fixed addresses and are highly mobile, migrating back and forth between the city and the provinces. Some of the middle-class patients gave false names and addresses and neglected to return for follow-up examination after an obviously stable state had been achieved. Interestingly, none of our patients filed a criminal complaint against their attackers.

**TABLE I Patient and Management Data**

Patient	Age (yr)	Occupation	Hours Until Surgery	Cause	Weapon	Extent	Procedure	Complications	Sexual Function
1	42	Farmer	2	A?	Shovel	P	DA	PNS	NFU
2	28	Laborer	2.5	MFA	Knife	T	DA	NS,PNG	NFU
3	35	Laborer	2	MFA	Razor	T	DA	NS,PNG	Yes
4	36	Merchant	2	MFA	Knife	P	DA	NS,PNG	NFU
5	34	Merchant	4	SF	Knife	P	DA	PNS	NFU
6	38	Vendor	2.5	MFA	Razor	T	DA	NS,PNG	Yes
7	40	Laborer	0.5	MFA	Knife	T	DA	NS,PNG	Yes
8	44	Employee	1.5	MFA	Knife	P	DA	PNS	NFU
9	41	Employee	2.5	SF	Knife	P	DA	None	NFU
10	34	Civil servant	2	MFA	Knife	T	DA	NS,PNG	Yes
11	33	Laborer	5	MFA	Razor	T	DA	NS,PNG	NFU
12	32	Merchant	8	SF	Razor	T	DA	NS,PNG	NFU
13	36	Civil servant	2	MFA	Knife	T	DA	PNS,PNG	Yes
14	20	American student	6	SF	Razor	T	DA	TN	
15	34	Unknown	2	MFA	Knife	T	SB	PNG	Yes
16	34	Unknown	4	MFA	Knife	T	SB	none	Yes
17	32	Employee	2	MFA	Knife	P	SB	none	NFU
18	40	Laborer	2	MFA	Knife	T	SB	none	Yes

A? = questionable accident. DA = direct anastomosis; MFA = male-female altercation; NFU = no follow-up; NS = necrosis of the skin; P = partial amputation (residual stump); PNG = partial necrosis of the glans; PNS = partial necrosis of the skin; SB = scrotal burring; SF = self-inflicted; T = total amputation (no stump); TN = total necrosis.

### Summary

Thailand recently experienced an epidemic of penile amputations. These were usually performed by angry wives on philandering husbands. This outbreak appeared to have been fueled by graphic press reports and fortunately seems to have abated. A technique for reanastomosis of the amputated penile segment was first described by McRoberts et al [5] in 1968. It was modified further so that it can be performed in any general hospital with an acceptable result. Experience with this procedure in 18 patients has been described.

### References

1. Ehrish WS. Two unusual penile injuries. *J Urol* 1929;21:239-41.
2. Galleher EP Jr, Kiser WS. Injuries of the corpus cavernosum. *J Urol* 1961;85:949-52.
3. Ahmand S. Cut penis: a short case of reconstruction. *Br J Plast Surg* 1961;14:59-65.
4. Best JW, Angelo JJ, Milligan B. Complete traumatic amputation of the penis. *J Urol* 1962;87:134-8.
5. McRoberts JW, Chapman WH, Ansell JS. Primary anastomosis of the traumatically amputated penis: case report and summary of literature. *J Urol* 1968;100:751-4.
6. Tuerk M, Weir WH Jr. Successful replantation of a traumatically amputated glans penis. *Plast Reconstr Surg* 1971;48:499-502.
7. Mendez R, Kiely WF, Morrow JW. Self emasculation. *J Urol* 1972;107:981-5.
8. Schulman KL. Reanastomosis of the amputated penis. *J Urol* 1973;109:432-3.
9. Enyelman ER, Pobto G, Perly J, et al. Traumatic amputation of the penis. *J Urol* 1974;112:774-8.
10. Cecil AB. Repair of hypospadias and urethral fistula. *J Urol* 1946;56:237-42.